



Evidence for potentials and limitations of brain plasticity using an atlas of functional resectability of WHO grade II gliomas: Towards a “minimal common brain”

Tamara Ius^a, Elsa Angelini^b, Michel Thiebaut de Schotten^{c,d}, Emmanuel Mandonnet^{e,f}, Hugues Duffau^{g,h,*}

^a Department of Neurosurgery, Udine, Italy

^b Institut Telecom, Telecom ParisTech, CNRS LTCI, Paris, France

^c Natbrainlab, Department of Forensics and Neurodevelopmental Sciences, Institute of Psychiatry, King's College London, London, UK

^d INSERM-UPMC UMR S 975, G.H. Pitié-Salpêtrière, Paris, France

^e Department of Neurosurgery, Lariboisière Hospital, Paris, France

^f INSERM U678, Paris, France

^g Department of Neurosurgery, Hôpital Gui de Chauliac, CHU Montpellier, 80 Av Augustin Fliche, 34295 Montpellier, France

^h Institut of Neuroscience of Montpellier, INSERM U1051, Plasticity of Central Nervous System, Human Stem Cells and Glial Tumors, Hôpital Saint Eloi, CHU Montpellier, 80 Av Augustin Fliche, 34091 Montpellier, France

ARTICLE INFO

Article history:

Received 22 December 2010

Revised 6 March 2011

Accepted 8 March 2011

Available online 14 March 2011

Keywords:

Brain plasticity

Direct electrical stimulation

Glioma surgery

Intraoperative functional mapping

Probabilistic atlas

White matter connectivity

ABSTRACT

Despite recent advances in non-invasive brain mapping imaging, the resectability of a given area in a patient harboring a WHO grade II glioma cannot be predicted preoperatively with high reliability, due to mechanisms of functional reorganization. Therefore, intraoperative mapping by direct electrical stimulation remains the gold standard for detection and preservation of eloquent areas during glioma surgery, because it enables to perform on-line anatomo-functional correlations. To study potentials and limitations of brain plasticity, we gathered 58 postoperative MRI of patients operated on for a WHO grade II glioma under direct electrical cortico-subcortical stimulation. Postoperative images were registered on the MNI template to construct an atlas of functional resectability for which each voxel represents the probability to observe residual non-resectable tumor, that is, non-compensable area. The resulting atlas offers a rigorous framework to identify areas with high plastic potential (i.e. with probabilities of residual tumor close to 0), with low compensatory capabilities (i.e. probabilities of residual tumor close to 1) and with intermediate level of resectability (probability around 0.5). The resulting atlas highlights the utmost importance of preserving a core of connectivity through the main associative pathways, namely, it supports the existence of a “minimal common brain” among patients.

© 2011 Elsevier Inc. All rights reserved.

Introduction

Current developments in functional mapping and neuroimaging techniques have radically changed the classical static view on the functional organization of cortical areas, for a new dynamic perspective of the brain (Duffau, 2005). Indeed, many recent investigations have highlighted the dynamic capability of the brain to reorganize itself, both during everyday life (i.e. learning) and after a pathological event (e.g. stroke or glioma). This reorganization would be based on the existence of multiple and overlapping redundancies hierarchically organized (Bavelier and Neville, 2002; Duffau, 2001; Duffau et al., 2000; Rossini et al., 2003; Sanes et al., 1995; Schieber and Hibbard, 1993). These findings have testified that neuronal aggre-

gates, beside or outlying a lesion, can increasingly adopt the function of the damaged area and switch their own activation pattern to substitute the lesioned area while facilitating functional recovery following brain damage (Duffau, 2006a). Advances in neuroimaging have enabled a better comprehension of the dynamic interaction between a tumor and functional cortical sites, usually preoperatively assessed by non-invasive functional examinations such as positron emission tomography (PET), functional magnetic resonance imaging (fMRI), MRI-based diffusion tensor imaging (DTI) and magnetoencephalography (MEG). Nevertheless, despite efforts to improve these techniques, their sensitivity and specificity are still limited due to perturbations induced by tumor on local neurovascular and metabolic coupling (sensitivity for the identification of sensorimotor sites ranges from 82% to 100%, whereas it ranges from 66% to 100% for language sites) (Aubert et al., 2002; Bartos et al., 2009; Roux et al., 2003) and neuroimaging is not able to differentiate essential cortical areas (which should be surgically preserved) from the “modulatory” areas that can be functionally compensated and resected without inducing permanent deficits (Duffau et al., 2003).

* Corresponding author at: Department of Neurosurgery, Hôpital Gui de Chauliac, CHU Montpellier, 80 Avenue Augustin Fliche, 34295 Montpellier, France. Fax: +33 4 67 33 69 12.

E-mail address: h-duffau@chu-montpellier.fr (H. Duffau).

Axonal pathways also play a crucial role in glioma surgery, considering their infiltrative growth patterns along white matter fiber tracts (Chen et al., 2010; Mandonnet et al., 2006; Pallud et al., 2005). Recent developments in DTI have allowed to track non-invasively in vivo subcortical fibers (Catani et al., 2002; Catani and Thiebaut de Schotten, 2008) providing information on displacements, infiltrations or disruptions of fibers induced by the tumor (Witwer et al., 2002). Nevertheless, tracking algorithms may strongly influence the anatomical data of DTI (Kinoshita et al., 2005), even if some reports have provided some validation on postmortem studies (Thiebaut de Schotten et al., 2011; Lawes et al., 2008). Finally, DTI is not yet able to highlight the functional role of the tracts.

Considering (1) the large variability in structural and functional networks among healthy volunteers (Brett et al., 2002; Tzourio-Mazoyer et al., 2004), (2) functional limitations in neuroimaging, and (3) functional modifications induced by tumoral growing patterns both at cortical and axonal levels (Duffau, 2006a), the study of the brain functional cortical organization and connectivity is needed for individual patients to both select the best indications for surgery and to perform a resection with the optimal benefit/risk ratio. As a consequence, the use of intraoperative direct electrical stimulation (DES) is considered as the “gold standard” to detect both the eloquent cortical areas and subcortical pathways at the individual level (Duffau et al., 2008b; Mandonnet et al., 2010b). Indeed, DES provides accurate and real-time data on the distribution not only of the cortical eloquent areas (Ojemann et al., 1989; Sanai et al., 2008), but also of the functional white matter bundles (Bello et al., 2007; Duffau et al., 2008b; Sanai and Berger, 2010). Thus, DES allows to tailor the tumoral resection according to individual functional boundaries, maximizing the extent of resection while minimizing the risk of permanent neurological deficits.

Combining intraoperative anatomofunctional data with pre and post-operative fMRI and DTI imaging is currently the best approach to assess the functional role of the cortical areas and the white matter fiber tracts (Kamada et al., 2007). For this reason, we propose in this paper the elaboration of a probabilistic postsurgical residue atlas computed on a series of patients who underwent incomplete tumor resection on the basis of intraoperative DES brain mapping. The anatomic-functional correlations we obtained by combining the DES data with postoperative anatomical MRI findings will provide a greater understanding of the functional limits of surgical removal, and will provide new insights into the potentials and limitations of brain plasticity. Especially, this probabilistic atlas highlights the crucial role of the axonal pathways in the reshaping and reorganization of the brain after a lesion. Finally, beyond its fundamental interest, we hope this atlas will be an essential tool for surgery planning, by allowing an objective pre-operative estimation of the expected extent of the resection.

Materials and methods

Patients

In this retrospective study, we analyzed a homogenous group, for radiological and neuropathological features, of 58 patients who underwent surgery for WHO grade II glioma (low-grade glioma, LGG) between 2005 and 2009. All the procedures were performed by the same neurosurgeon (H.D.). All patients had a lesion in eloquent regions, which required intraoperative functional mapping achieved with both cortical and subcortical stimulations. Considering that the aim of this study is to evaluate the limitations of brain plasticity, we focused our analysis on cases in which the tumor removal was subtotal (residual volume < 10 cm³) or partial (residual volume > 10 cm³) for functional reasons (i.e. presence of cerebral structures still eloquent as demonstrated by intraoperative electrostimulation mapping

while already invaded by the glioma), according to the classification method reported by Berger et al. (Berger et al., 1994; Sanai and Berger, 2008). The preoperative volume and the postoperative tumoral residual volume were computed on FLAIR-weighted MRI images.

Patients included 30 men and 28 women, ranging in age from 19 to 61 years (average age 38 years). The presenting symptoms were seizures in all cases (34 generalized, 24 partial). The preoperative neurological clinical examination was normal in 56 patients. Two patients, harboring lesions in the temporo-parieto-occipital junction, presented a preoperative visual field deficit.

Intraoperative direct cerebral stimulation

All patients had a tumor located near or within so-called “eloquent” areas. In consideration of individual anatomofunctional variability, intraoperative electrocortical and subcortical white matter stimulations were employed in all cases in order to define real-time functional maps and tailor LGG resection in accordance with functional boundaries. In this process, techniques previously described by one of the authors (H.D.) (Duffau et al., 2002) and based on the methodology of Berger and Ojemann (1992), Berger et al. (1990) and Ojemann et al. (1989) were used. Patients with lesions located in somatosensory area and in the dominant temporal, premotor lobe as well as the insula and inferior parietal lobule were operated under local anesthesia (43 cases) while intraoperative sensori-motor and language mapping were performed. Conversely, patients harboring lesions involving non-dominant supplementary, primary motor area, insular and temporal lobes underwent surgery under general anaesthesia (15 cases) in which cortical and subcortical DES enabled the detection of cortico-spinal pathways. Cortical and subcortical brain mapping were performed using direct electrical stimulations with a bipolar electrode with 5 mm spaced tips delivering a biphasic current (pulse frequency of 60 Hz; single-pulse phase duration of 1 ms; amplitude between 1 and 8 mA). (Nimbus*, Newmedic, Hemodia, Labège, France). In the first phase of the surgical procedure, cortical mapping was performed before resection to avoid any damage to the eloquent cortical areas. The current intensity was adapted to each patient and was determined by progressively increasing the amplitude by 0.5 mA steps, from a baseline of 1 mA, until a sensory-motor response was elicited. Usually, 4 mA was the maximum stimulus needed to localize the eloquent areas in awake patients, whereas up to 8 mA was needed to localize the motor cortex under general anesthesia. The upper amplitude limit was set to 8 mA, to avoid the generation of seizures. Sensory-motor mapping was systematically tested to confirm a positive response (e.g. the induction of movement and/or paresthesia in the contralateral hemibody when the primary sensory motor areas were stimulated in a patient at rest). In addition to motor mapping, for patients under local anesthesia, counting, picture naming, and reading tests were systematically performed, so that the essential cortical language sites, known to be inhibited by stimulation, could be identified. Moreover a calculation task was added if a patient harbored a lesion in the left angular and supramarginal gyri, a repetition and/or semantic task if the lesion was within left mid-posterior temporal lobe, and a bisection line task when the tumor involved the temporo-parieto-occipital region.

Patients were not informed of the timing of stimulation. Stimulations lasted less than 4 s. For the picture-naming task, at least one picture presentation without stimulation separated each stimulation, and no site was stimulated twice in succession in order to avoid seizures. In accordance with previous studies (Ojemann et al., 1989), a cortical site was considered essential for language when its stimulation induced speech disturbance during the three trials. In the second surgical phase, direct stimulation with the same electrical parameters as those used at the cortical level was

continuously applied during lesion removal at the subcortical level to detect and preserve the subcortical pathways in order to tailor the deep functional limits of resection. In this setup all lesions were removed by alternating resection and subcortical stimulation following progressively the functional pathways from the cortical eloquent sites, mapped in the first surgical stage, to the depth of the resection. Each cortical area and subcortical pathways were considered eloquent if a functional disturbance was generated during the course of the intraoperative tasks mentioned above, consistently on at least two separate trials. To perform the best possible tumor removal while sparing the functional areas, all resections were pursued until eloquent pathways (for sensory-motor function as well as for language and cognitive functions) were encountered in the border of the surgical cavity, as determined by the subcortical stimulation. Therefore no margin was left around cortico-subcortical eloquent areas.

Probabilistic mapping of the residues: methodological procedure

We used MRI images acquired 3 months after surgery to compute an atlas of tumoral residues. The three months delay was chosen based on the facts that anatomical structures may be displaced immediately after surgery (because of the presence of edema or subdural collection), and that the residual tumor is not subject to experience re-growth in the meantime for LGG. Indeed, it has been recently demonstrated that in the postoperative period, LGG exhibits growth rates around 4 mm/year (Mandonnet et al., 2010a). Magnetic resonance images were acquired with a 1.5T scanner, including high-resolution T1-weighted SPGR images, and either FLAIR or 3DFLAIIR images. Slice thickness ranged between 1 mm and 5 mm and axial resolution was 0.5mm².

The total lesion (defined as the residual tumor + the resection cavity) and the residual tumor were successively manually segmented on original FLAIR images by the first author (with the OSIRIX software tool (Rosset et al., 2004)), and then spatially registered to the Montreal Neurological Institute (MNI) space (Evans et al., 1992).

Registration to the MNI was performed by applying nonlinear spatial transformations with the FSL software tool (available at <http://www.fmrib.ox.ac.uk/fsl>) to the FLAIR data (Smith et al., 2004; Woolrich et al., 2009). More specifically, we used the FNIRT non-linear registration tool (Diedrichsen et al., 2009; Klein et al., 2009).

Registration of an individual patient on the MNI atlas was based on three steps. First, an affine rigid spatial transformation that mapped the intra-patient FLAIR data along with the segmented residual tumoral lesions on the SPGR data was applied, using the normalized mutual information as the homogeneity measure. Second, a non-linear registration of the SPGR data onto the T1-based MNI atlas was applied, initialized by an affine transform computed with a normalized correlation measure, and using the rigidly registered tumor mask to exclude the tumor region from the computation on the diffeomorphic non-linear wrapping, using a sum of square differences as the cost function. This spatial normalization relied on similar tools as developed for lesion analysis in other neurological fields (especially for lesion analysis in stroke). In particular the registration process first required a manual segmentation of the total lesion, which has to be excluded from the normalization itself, to reduce potential distortions generated by the nonlinear transformation. Finally, the same non-linear wrapping was applied to the segmented FLAIR data to align all lesion masks on the MNI anatomy.

From the spatially registered lesion and residue masks, statistical maps were obtained (specific Matlab procedure, written by E. A.), for tumor overlap (by computing for each voxel the cumulative number of observed lesions) and for residual tumor index (by computing for each voxel the ratio between the number of residual tumors and observed lesions). This final statistical map was

overlapped on the 3D statistical renderings of a white matter atlas recently published (Thiebaut de Schotten et al., 2011). The overall visualization and screenshots were performed in Anatomist (<http://brainvisa.info>).

In summary, the methodological procedure is very similar to the one used in our previous work (Mandonnet et al., 2007a), with the following modifications:

- all segmentations are now performed on FLAIR images, and the registration algorithms have been modified accordingly,
- the resulting atlas can be superimposed on an atlas of white matter tracts (obtained from a DTI atlas), allowing to analyze the resectability of each pathway.

Results

Patients

Among the 58 lesions, the right hemisphere was involved in 25 cases and the left in 33 cases. The median preoperative tumoral volume was 65 cm³ (range: 15–202 cm³). Patients with right-sided lesions displayed a right dominant hemisphere in 10 cases. The hemispheric dominance was established using the Edinburgh test and the index of dominance was calculated on the basis of fMRI findings (Gaillard et al., 2002). In particular preoperative MRI revealed 24 precentral lesions (8 on the right side and 16 on the left side), 3 right postcentral lesions, 23 lesions with the involvement of the insular lobes (10 on the right side and 13 on the left side), 3 lesions in temporo-parieto-occipital junctions (2 on the right side and 1 on the left side) and 5 in the temporal lobes (2 on the right side and 3 on the left side). The map of tumor overlap (Fig. 1, top) confirms that in this series, tumors were predominantly located in frontal, temporal and insular lobes. Lesions were exclusively located within or near functional areas. Thus, during intraoperative functional mapping, sensory-motor functions were systematically tested, and language functions were tested for 43 patients. According to the Berger's classification (Berger et al., 1994; Sanai and Berger, 2008), the postoperative FLAIR-weighted MRI showed a subtotal removal in 38 cases (65.5%), and a partial resection in 20 cases (34.5%). The median residual volume was 9.7 cm³ (range, 2–25 cm³).

Results of the neuropathological examinations revealed a WHO grade II glioma in all cases. Despite an immediate postoperative worsening in 14 cases (24%), on examination at 3 months after surgery, the neurological status had improved in all cases and returned to the initial level or better.

Probabilistic atlas

Fig. 1 illustrates the resulting probabilistic map on the cortical surface. Probabilities are encoded in a chromatic scale. The probability of leaving a functional tumoral residue, according to the color code, increases as the color changes from green to yellow and finally to red. In particular, regions in red color correspond to the sites that can never be resected, because of their invariant functional role. Regions in green color refer to areas that are resectable. Yellow regions represent areas with an intermediate probability of resectability. Finally, transparent regions indicate areas where no preoperative tumor was observed, that is without any information about resectability.

Analyzing the results in greater detail at the cortical level, the atlas indicates a high probability of residual tumor (i.e. a very low functional resectability) in the following areas:

- on the left side: the primary motor and somatosensory areas for upper and lower limbs, the ventral premotor cortex (vPMC), the posterior part of superior temporal gyrus (Wernicke's area), the supramarginal gyrus, and the angular gyrus,

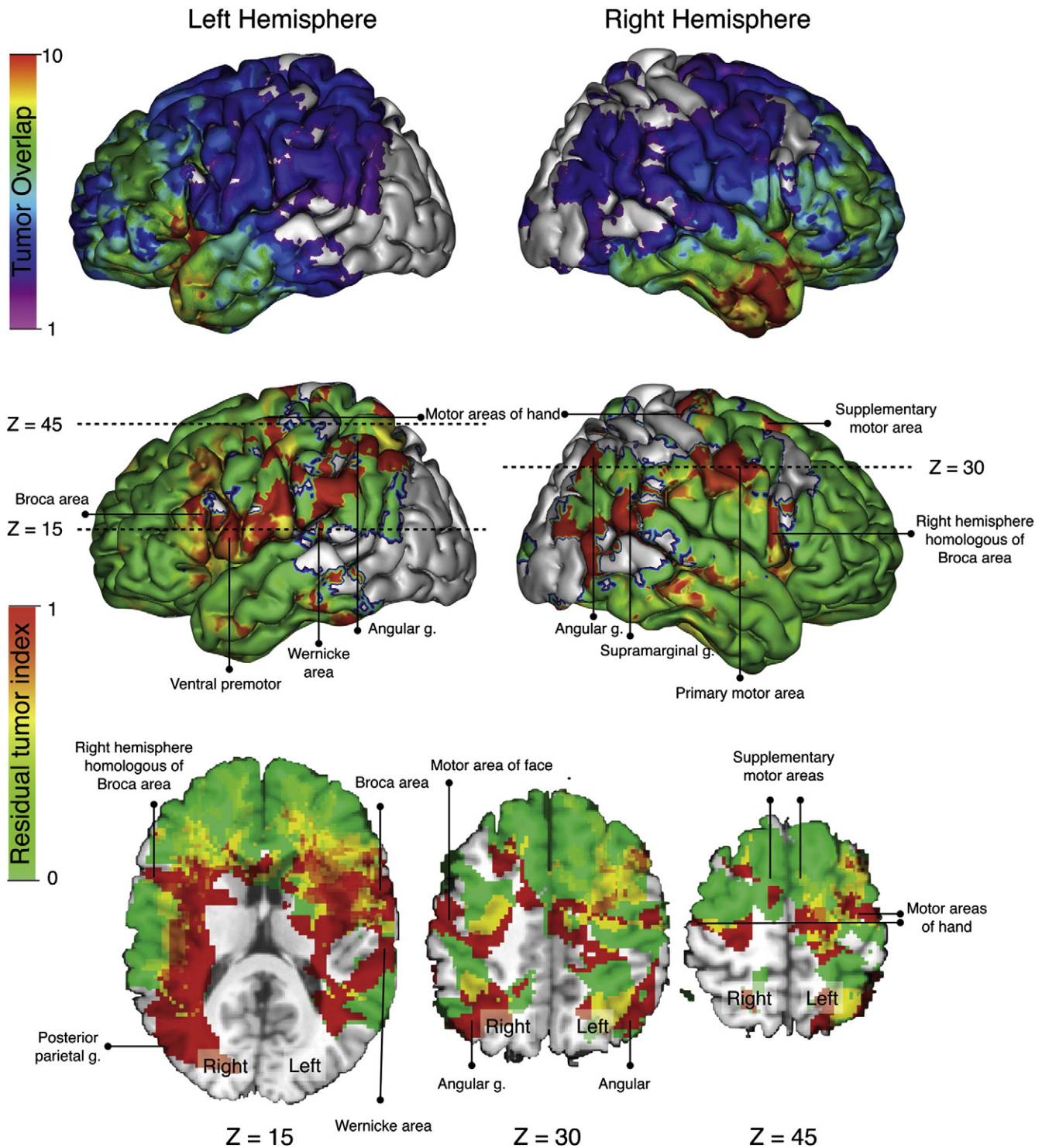


Fig. 1. Resulting statistical map on the cortical surface. Top: distribution of tumors prior to resection (tumor overlap). Bottom: probabilities of residual tumor after resection (residual tumor index).

- on the right side: the primary motor and somatosensory areas for superior and inferior limbs and the angular gyrus.

All other cortical areas appear to be resectable, including the left and right Supplementary Motor Areas (SMA) and the primary non-dominant sensorimotor area of the face (regions visualized in green), and to a lesser extent, Broca's area and insular lobes (represented in yellow).

Fig. 2 superimposes the residual atlas to the fiber tracts atlas. Few pathways appear to be resectable:

- the anterior part of the corpus callosum and cingulate area (on both sides),
- right and left uncinate fasciculus,
- anterior part of right and left inferior longitudinal fasciculus.

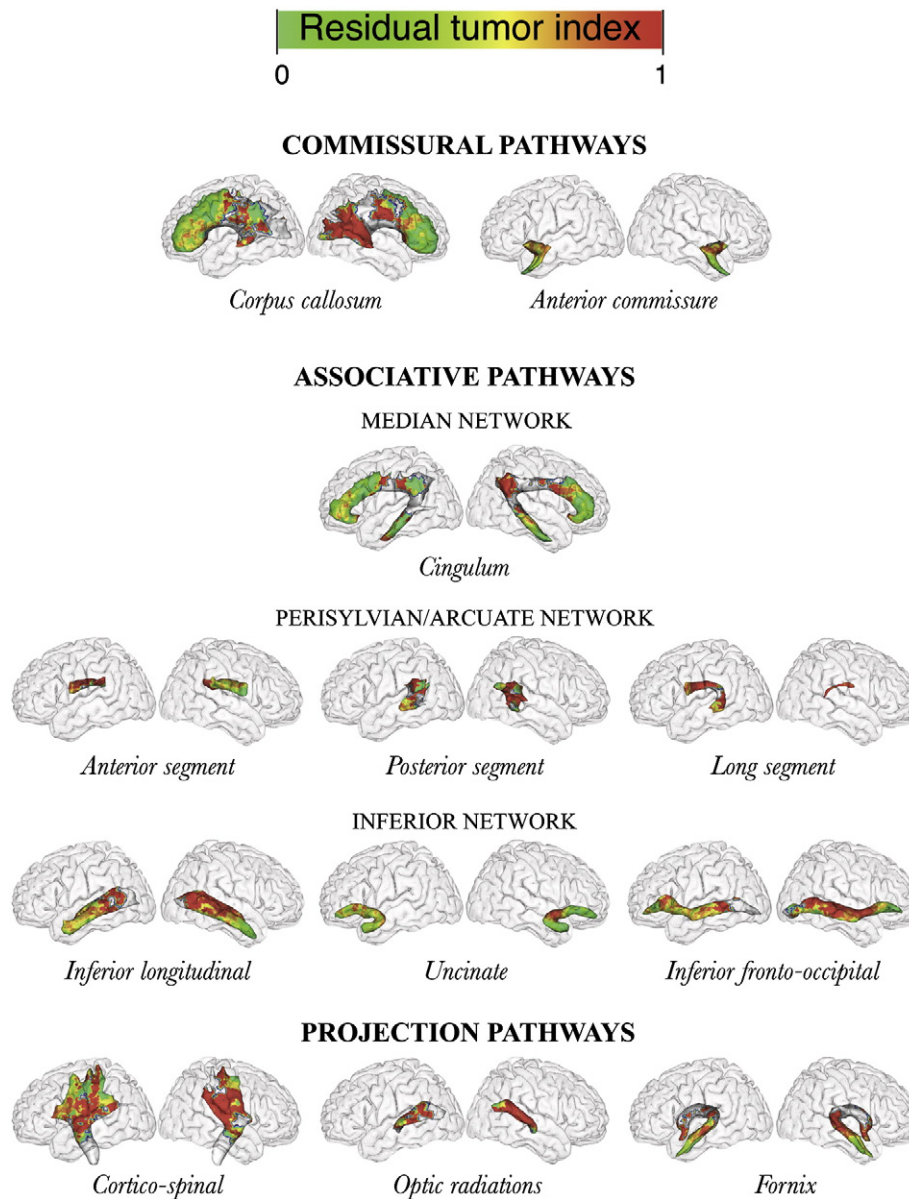


Fig. 2. Superimposition of the probabilistic map of residual tumor to the white matter fiber atlas.

All other tracts, on both sides, appear to be non-resectable (or at least, of intermediate resectability):

- the cortico-spinal tract, just under the primary motor area, and deeply at the level of the corona radiata (posterior limits of resection in patients with a frontal precentral glioma) and in correspondence to both the internal capsule and the superior part of the mesencephalic peduncles (which represent the depth of resection in patient with fronto-temporo-insular glioma),
- the thalamo-cortical tract (anterior limit of resection in patients with a parietal glioma),
- the stratum sagittale (including optic radiations, posterior part of inferior longitudinal fasciculus and inferior fronto-occipital fasciculus), defining the medial functional boundaries during the resection of temporo-parietal gliomas,
- the anterior part of the inferior fronto-occipital fasciculus, that represents the deep limit of resection in patients with gliomas involving tumors in the left insular lobe, in the pars orbitalis of the left inferior frontal gyrus and in the dorsolateral prefrontal area,

- the perisylvian network, both on the left and right sides (see Duffau et al. (2002, 2008a); Thiebaut de Schotten et al. (2005) for extensive discussion on the glioma locations for which these network will be detected by DES).

Discussion

A new tool to study the potentialities and limitations of interindividual variability and plasticity in patients with LGG

Low-grade gliomas are slow-growing tumors, but hamper functional prognosis, as they infiltrate functional areas, and are ultimately prone to undergo anaplastic transformation (Wessels et al., 2003). Numerous pre-operative neurofunctional imaging studies have shown that tumor invasion triggers a neural reorganization, explaining the fact that a majority of LGG patients exhibit normal clinical exams (Walker and Kaye, 2003), even if slight cognitive disorders can be detected using extensive assessments (Taphoorn and Klein, 2004). Four main plastic patterns have been reported: first, the infiltrative

character of LGG makes it possible for the function to persist within the tumor; second, eloquent areas can be redistributed immediately around the tumor; third, a distributed network of areas can be recruited within the lesioned hemisphere; finally, a network of areas can be recruited in the contralateral hemisphere (Duffau, 2006b). Therefore, slow growing tumors represent an accurate model to study in vivo the interactions between the tumor growth and the capability of the whole cerebral network to reorganize itself (Desmurget et al., 2007).

Combinations of different neurofunctional imaging methods (such as fMRI, PET, and MEG) have enhanced our understanding of the individual pre-operative organization of the functional networks and their eventual postoperative reshaping. As these functional mapping techniques provide information only about cortical areas, an increasing number of clinical neuroimaging studies now rely on diffusion tensor imaging (DTI), in order to provide new in vivo information about white matter fiber tracts. However, DTI does not provide the functional role of these tracts, but rather their 3D anatomy. Moreover, tractography results are not fully reliable, as they depend on the mathematical algorithms used to perform the tracking (Burgel et al., 2009; Catani, 2007; Dell'acqua et al., 2010).

Linking the precise functional disturbances evoked by cortical and axonal stimulations in LGG surgery to the anatomical data provided by postoperative MRI has enabled reliable anatomo-functional correlations, especially for axonal pathways (Duffau, 2009c). In particular DES allows the discrimination of the *essential* cortical and axonal areas (which should be surgically preserved) from modulatory areas (which can be activated on non-invasive functional imaging but nevertheless removed without inducing permanent deficits) (Krainik et al., 2004; Roux et al., 2003). While the aim of intraoperative electrical stimulation is primarily to optimize the resection extent while preserving functional areas for each patient, pooling of data on series of patients offers a powerful tool to analyze which parts of the brain are subject to inter-individual variability and plasticity and which are not. Such systematic studies have been, up to now, exclusively devoted to cortical areas (Ojemann et al., 1989; Sanai et al., 2008). The present work provides a general framework to establish anatomo-functional correlations by computing for each brain voxel its probability to be left – due to its functional role – on the postoperative MRI. Its overlap with the cortical MNI template and a DTI atlas offers a unique tool to analyze the potentialities and the limitations of inter-individual variability and plasticity, both for cortical areas and axonal pathways.

General overview

In line with our previous work (Mandonnet et al., 2007a), we observed as a rule a low probability of residual tumors on the cortical surface, whereas most of the regions with high probability of residual tumor are located in the deep white matter. Thus, projection and association axonal pathways seem to play a critical role in the proper functioning of the brain. In other words, the functions subserved by long-range axonal pathways seem to be less subject to inter-individual variability and reorganization than cortical sites. Consequently, these pathways define the surgical deep limits (Duffau et al., 2008c) and, since LGG infiltrate these tracts (Mandonnet et al., 2006; Pallud et al., 2005), they constitute the main obstacle to radical surgical resection.

Another striking feature of the resectability atlas is that it appears to be roughly symmetrical. This can be explained by a selection bias: patients with right lesions had a right-dominant hemisphere in only 10 out of 25 cases. The symmetrical aspect of the non-resectable areas between left and right side thus argues in favor of previous studies evidencing in the right dominant hemisphere an organization of language networks similar to that observed in left dominant hemisphere (Duffau et al., 2008a). Last but not least, some areas on the right side have been preserved during surgery because of their participation in functions other than sensory-motor or language

Table 1
Functional responses of electrical stimulation for non-resectable cortical areas.

Location of stimulation	Task	Effect
Primary motor area (left or right)	Rest	Unvoluntary movement of contralateral limb
Primary somatosensory area (left or right)	Rest	Paresthesias in the contralateral limb
Left ventral premotor cortex	Counting	Speech arrest (counting)
Left posterior part of superior temporal gyrus (Wernike's area)	Picture naming	Anomia/phonological paraphasias
Left supramarginal gyrus	Picture naming	Speech arrest/phonological paraphasias
Left angular gyrus	Picture naming	Phonemic paraphasias/leftward deviation
Right angular gyrus	Line bisection	Rightward deviation

abilities (see *infra* for exhaustive listing), like spatial consciousness for example.

Analysis of non-resectable areas: the limitations of inter-individual variability and plasticity

Although the present methodology does not give direct access to the functional deficit elicited by their electrical stimulation, the observed transient disturbances can nevertheless be inferred for each case from the operative report. Tables 1 and 2 report the effects of electrical stimulation for these non-resectable areas, for cortical and axonal sites, respectively.

Two questions arise on why there is no inter-individual variability for these areas and why their resection cannot be efficiently compensated by plasticity phenomena. For some of these areas, the explanation could be that they act as input or output areas: input sites convey or are the first relay of information entering the brain, whereas output sites are the last relay or the fiber tracts sending information outside the brain. These areas include the primary motor and somatosensory areas, the cortico-spinal and thalamo-cortical tracts and the optic radiations, that is, the projection fibers. These areas are mainly unimodal and probably organized serially. The absence of parallel alternative pathway explains the impossibility to restore their function after any damage (Duffau, 2009b).

For all other areas, their non-resectability should be analyzed within a network perspective. High-order cognitive processes are mediated by short- and long-range networks, with cortical epicenters connected by U-shaped fibers, associative and commissural pathways and a particular network topology (like the “small world” one) is required to allow proper synchronization between several distant areas (Stam, 2010). The link between the function and the anatomy is not as simple as for input–output areas: here, a local lesion will disturb a whole network topology, which in turn could ultimately hamper the function sustained by this network. It can be hypothesized that structures like the Wernike's area, supramarginal and angular gyri, the inferior-fronto-occipital fasciculus and the arcuate fasciculus are non-resectable because their lesion would cause so major changes in the network topology that the dynamical plasticity potential¹ would be overwhelmed. Interestingly, these areas are considered as “hubs” in revisited models of cognition – e.g. the posterior part of the left dominant superior temporal gyrus and its junction with the inferior parietal lobule (Hickok and Poeppel, 2007). Indeed, these functional epicenters allow a plurimodal integration of multiple data coming from the unimodal areas. In a step forward, this

¹ The dynamical plasticity is the ability of brain networks to redistribute, after a focal injury, their global dynamical behavior over the intact areas, on a time scale ranging from seconds to hours. It is different from the biological plasticity, where biological changes in the properties of neurons and axons and their branching will allow brain function changes on a time scale from days to months.

Table 2
Functional effects of axonal electrostimulation for non-resectable subcortical areas.

Location of stimulation	Task	Effect
Cortico–spinal tract (left or right)	Rest	Unvoluntary movement of contralateral limb
Optic radiations (left or right)	Rest	Phosphenes in the contralateral visual hemifield
Arcuate fasciculus (dominant side)	Picture naming	Phonological paraphasias
Inferior fronto–occipital fasciculus (dominant side)	Picture naming	Semantic paraphasias
Perisylvian network (right side)	Line bisection	Rightward deviation

integration may lead to the conceptualization, performed at the level of a wide network which includes the hubs. As a consequence, these hubs are interconnected by subcortical pathways, themselves crucial for brain function, such as for instance the arcuate fasciculus or the inferior fronto-occipital fasciculus which enables a direct communication between the posterior temporal and frontal plurimodal regions. The reproducibility of these results, despite the inter-individual anatomic-functional variability and plastic mechanisms, may lead us to suggest the existence of a “minimal common brain”, necessary for the basic cognitive functions – even if likely not sufficient for more complex functions such as multi-processing. This hypothesis is in good agreement with recent biomathematical models, analyzing the effect of a simulated focal lesion on the whole brain network topology (Alstott et al., 2009). Note that for these areas, even biological plasticity – which has been shown to offer an axonal rewiring in animal models (Dancause et al., 2005; Guleria et al., 2008) – would fail on the long term to repair the connectivity required to rebuild an effective network topology, hence a functional network (Duffau, 2009b).

Analysis of resectable areas: the potential of plasticity

Regarding resectable areas, it should be kept in mind that the functional role of an area could have been missed, because of an inappropriate intraoperative task during electrical stimulation. For example, mood disorders are currently not tested during awake surgery. However, the good clinical status 3 months after surgery (as evidenced by extensive neuropsychological testing) argues for efficient plasticity mechanisms for these areas.

Different hypotheses have been proposed to explain the high plastic potential of these resectable areas (Duffau, 2009b; Duffau et al., 2003). In particular, the very low velocity of LGG expansion (about 4 mm/year, Mandonnet et al., 2003) certainly plays an important role, allowing the whole brain to continuously reorganize and implement compensatory networks (Desmurget et al., 2007). Interestingly, a computational model has been developed to unveil how the neural mechanisms of plasticity differ between acute versus low growing lesions (Keidel et al., 2010). Thus, preoperative reshaping of brain networks largely contributes the high plastic potential of resectable areas. Postoperative plasticity also accounts for the resectability of some areas. Again, these areas should be considered as nodes within a wide network: after their removal, the whole functional network will self-reorganize by dynamical and biological plasticity, and the function will finally be preserved. The importance of protecting connectivity (i.e. axonal pathways) within the intact part of the network cannot be overemphasized.

For example, the possibility to remove the primary non-dominant sensory-motor area of the face without inducing permanent central facial palsy is likely explained by the disinhibition of the contralateral homologous sites, via preserved transcallosal pathways (LeRoux et al., 1991). Similarly, the atlas shows a very low probability of residual tumor in the SMA. It has been shown by longitudinal fMRI studies that SMA resection is compensated by an overactivation within the

contralateral SMA and premotor cortex (Krainik et al., 2004). Although these contralateral areas may send information to the homolateral limb through uncrossed fibers, it is likely that intact transcallosal pathways linking contralateral SMA and premotor cortex to the primary motor area are involved in the compensatory mechanisms (Krainik et al., 2004).

Moreover the atlas clearly illustrates the resectability of the inferior longitudinal and uncinate fasciculi (Duffau et al., 2009; Mandonnet et al., 2007b) in patients with lesions involving the left temporal lobe or the orbitofrontal area, indicating that these fasciculi do not play an essential role in the language processes. This has been explained by the fact that the “semantic ventral stream” might be constituted by at least two parallel pathways, i.e. a direct pathway underlined by the IFOF, crucial for the language semantics (Duffau et al., 2005), and an indirect pathway subserved by the uncinate fasciculus and the inferior longitudinal fasciculus, which can be functionally compensated. In this perspective, the resectability of these two fasciculi is conditional to the preservation of the IFOF (Duffau, 2009b). However, more elaborated language tasks than picture naming demonstrated a participation of the left dominant uncinate fasciculus in the retrieval of proper names (Papagno et al., 2011).

Analysis of areas of intermediate resectability: the role of interindividual variability

The intermediate resectability of some areas should be considered as a direct consequence of methodological limitations. For example, a small error in the registration of a non-resectable area for some patients can generate an intermediate level in the vicinity of non-resectable areas.

This being said, the main explanation for intermediate resectability is the inter-individual variability of normal and pathological brain functions mapping. This inter-individual variability might pre-exist to the tumor growth (intrinsic variability) or arise as a consequence of tumorigenesis (inter-individual variability of plastic potential). It can also come from variability in tumor behavior (for example, bulky tumors displacing normal structures versus purely infiltrative tumors).

The so-called Broca's area is a good illustrative case of intermediate resectability. The possibility of surgical resection of LGG within the pars opercularis and triangularis of the left inferior frontal gyrus (Broca's area) without generating permanent language deficits has already been reported (Benzagmout et al., 2007; Lubrano et al., 2010; Peraud et al., 2004). The atlas confirms the possibility to remove Broca's area in a majority of cases. Given the fact that Broca's area is located just in front of the non-resectable ventral premotor cortex, one can hypothesize that the real motor area for speech output is the vPMC rather than Broca's area, the latter being probably involved in other components of language (like syntactic and phonological processes) (Sahin et al., 2009). Predicting for each patient on non-invasive pre-operative imaging if Broca's area could be resected or not remains a neuroscientific challenge. This underlines, once again, the inescapable importance of the individual intraoperative study with DES.

Methodological procedure

To compute this atlas we have improved a previously reported methodological procedure (Mandonnet et al., 2007a) and included a more precise analysis of axonal pathways, introducing the overlap between spatially normalized data and a DTI atlas.

A first issue of the proposed method arises from the limitations of DES (Mandonnet et al., 2010b). In particular, it has been shown that there could be some false positive in the detection of eloquent areas by DES, due to a non-physiological backward propagation of the current toward a distant essential area (Ishitobi et al., 2000). However such false positive has never been reported regarding axonal areas. In addition, as discussed previously, some areas could have been

considered as resectable because their function would have not been tested by the appropriate intraoperative task. For example, it has been recently shown that the uncinata fasciculus, while not detected as essential during intraoperative picture naming test, could participate to other cognitive functions, like social processing or proper name retrieval (Papagno et al., 2011). Nonetheless, the good post-operative status evidenced by neuropsychological testing 3 months after surgery in all patients proves that the possibly missed functions do not preclude a normal socio-professional life.

Generation of probabilistic brain atlases by means of spatial normalization of individual MRI scans has proved to be a powerful tool for the analysis of normal brain structures and organization of normal brains (e.g. functional studies of healthy volunteers) as well as pathological brains (e.g. lesion analysis in stroke, neuropsychiatric disorders, brain tumors). Spatial normalization, as used in this study, enabled to elaborate a homogeneous population-based reference of spatial distribution of LGG functional residues.

Alignment was systematically reviewed visually and there were no aberrant results. Indeed, a visual inspection, for every subject, of the spatial relationships between the lesion on the original MRI scans and their registered counterparts provided a qualitative validation of our registration procedure. Moreover, special analysis of non-resectable anatomical structures confirmed both the reliability and the accuracy of the registration procedure. In particular, the posterior part of the corpus callosum and the anterior perforating substance appear on the map among the non-resectable anatomical structures. In fact, it is well known that the resection of the former area may cause severe adverse effects (e.g. cognitive impairment, disconnection syndrome, visuo-motor ataxia as a consequence of a damage at the level of the splenium of the corpus callosum) (Duffau et al., 2004), while vascular damage of the lenticulostriate vessels contained in the anterior perforating substance can cause ischemia of the internal capsule (Duffau, 2009a) – leading the surgeon to leave residual tumor in both instances. Therefore, the presence on the map of these areas as non resectable – as formerly underlined in the previous paper (Mandonnet et al., 2007a) – represents a first validation of such procedure. In addition the consistency between the atlas results and the functional literature in glioma surgery validates further our methodology.

However, several limitations could affect the accuracy of the methodology used to build the residues atlas. First, there is a patient selection bias, which limits the spectrum of lesions being covered. As illustrated in Fig. 1, in some areas, the probabilities of residual tumor are computed on very small numbers of cases, limiting the statistical significance of the resulting residual tumor index. This issue might be partially solved by including a larger number of cases in the population sample. Second, during registration on a normal brain template, mismatch may be due to the presence, size, location and signal of the tumoral lesion. Masking of the tumoral area, based on manual tracing, was used to minimize such mismatch and overall registration errors. Moreover, this procedure allows nonlinear transformation, without causing severe distortions in the lesioned image. Nonlinear transformation can greatly improve the quality of the normalization, both for normal brains and diseased brains (Ashburner and Friston, 1999). The masking technique does not work well when the size of the tumoral cavity and/or the ventricular system is large relative to the brain volume of the template. As a consequence, on the basis of this methodological limitation, we excluded from the study cases with enlarged ventricles or very large postsurgical cavities.

Conclusions and perspectives

The proposed atlas of functional resectability of WHO grade II glioma provides a new generic tool to study the potentials and limitations of brain plasticity and the role of interindividual variability for resection of WHO grade II gliomas. In addition, our atlas highlights the existence of a “minimal common brain” among patients.

Several ways can be foreseen to improve the quality of the present work:

- to enhance the accuracy of the registration procedure in order to optimize the spatial resolution of the atlas, for example by using algorithms based on biomathematical models of tumoral growth (Gooya et al., 2010),
- to increase the number of included patients, providing a higher confidence in the statistical results. To achieve this purpose, an on-line tool could be created to facilitate inclusion of patients from several collaborative centers.
- to correlate for each patient the intraoperative errors elicited by DES in the white matter pathway with the location of the residues, providing a new tool for lesion-behavior mapping (Kinkingnehun et al., 2007; Rorden et al., 2009).

Finally, apart from its fundamental interest in terms of lesion-behavior mapping, the present atlas can be used to predict individually, before surgery, the expected extent of the resection, by computing the overlap between the atlas and the preoperative MRI. Such a tool could play a role in the design of clinical trials – for example, to guide the decision between surgery or chemotherapy as first line of treatment.

References

- Alstott, J., Breakspear, M., Hagmann, P., Cammoun, L., Sporns, O., 2009. Modeling the impact of lesions in the human brain. *PLoS Comput. Biol.* 5, e1000408.
- Ashburner, J., Friston, K.J., 1999. Nonlinear spatial normalization using basis functions. *Hum. Brain Mapp.* 7, 254–266.
- Aubert, A., Costalat, R., Duffau, H., Benali, H., 2002. Modeling of pathophysiological coupling between brain electrical activation, energy metabolism and hemodynamics: insights for the interpretation of intracerebral tumor imaging. *Acta Biotheor.* 50, 281–295.
- Bartos, R., Jech, R., Vymazal, J., Petrovicky, P., Vachata, P., Hejcl, A., Zolal, A., Sames, M., 2009. Validity of primary motor area localization with fMRI versus electric cortical stimulation: a comparative study. *Acta Neurochir. (Wien)* 151, 1071–1080.
- Bavelier, D., Neville, H.J., 2002. Cross-modal plasticity: where and how? *Nat. Rev. Neurosci.* 3, 443–452.
- Bello, L., Gallucci, M., Fava, M., Carrabba, G., Giussani, C., Acerbi, F., Baratta, P., Songa, V., Conte, V., Branca, V., Stocchetti, N., Papagno, C., Gaini, S.M., 2007. Intraoperative subcortical language tract mapping guides surgical removal of gliomas involving speech areas. *Neurosurgery* 60, 67–80 discussion 80–62.
- Benzagmout, M., Gatignol, P., Duffau, H., 2007. Resection of World Health Organization grade II gliomas involving Broca's area: methodological and functional considerations. *Neurosurgery* 61, 741–752 discussion 752–743.
- Berger, M.S., Ojemann, G.A., 1992. Intraoperative brain mapping techniques in neuro-oncology. *Stereotact. Funct. Neurosurg.* 58, 153–161.
- Berger, M.S., Ojemann, G.A., Lettich, E., 1990. Neurophysiological monitoring during astrocytoma surgery. *Neurosurg. Clin. N. Am.* 1, 65–80.
- Berger, M.S., Deliganis, A.V., Dobbins, J., Keles, G.E., 1994. The effect of extent of resection on recurrence in patients with low grade cerebral hemisphere gliomas. *Cancer* 74, 1784–1791.
- Brett, M., Johnsrude, I.S., Owen, A.M., 2002. The problem of functional localization in the human brain. *Nat. Rev. Neurosci.* 3, 243–249.
- Burgel, U., Madler, B., Honey, C.R., Thron, A., Gilsbach, J., Coenen, V.A., 2009. Fiber tracking with distinct software tools results in a clear diversity in anatomical fiber tract portrayal. *Cent. Eur. Neurosurg.* 70, 27–35.
- Catani, M., 2007. From hodology to function. *Brain* 130, 602–605.
- Catani, M., Thiebaut de Schotten, M., 2008. A diffusion tensor imaging tractography atlas for virtual in vivo dissections. *Cortex* 44, 1105–1132.
- Catani, M., Howard, R.J., Pajevic, S., Jones, D.K., 2002. Virtual in vivo interactive dissection of white matter fasciculi in the human brain. *Neuroimage* 17, 77–94.
- Chen, X., Dai, J., Jiang, T., 2010. Supratentorial WHO grade II glioma invasion: a morphologic study using sequential conventional MRI. *Br. J. Neurosurg.* 24, 196–201.
- Dancause, N., Barbay, S., Frost, S.B., Plautz, E.J., Chen, D., Zoubina, E.V., Stowe, A.M., Nudo, R.J., 2005. Extensive cortical rewiring after brain injury. *J. Neurosci.* 25, 10167–10179.
- Dell'acqua, F., Scifo, P., Rizzo, G., Catani, M., Simmons, A., Scotti, G., Fazio, F., 2010. A modified damped Richardson–Lucy algorithm to reduce isotropic background effects in spherical deconvolution. *Neuroimage* 49, 1446–1458.
- Desmurget, M., Bonnetblanc, F., Duffau, H., 2007. Contrasting acute and slow-growing lesions: a new door to brain plasticity. *Brain* 130, 898–914.
- Diedrichsen, J., Balsters, J.H., Flavell, J., Cussans, E., Ramnani, N., 2009. A probabilistic MR atlas of the human cerebellum. *Neuroimage* 45, 39–46.
- Duffau, H., 2001. Acute functional reorganization of the human motor cortex during resection of central lesions: a study using intraoperative brain mapping. *J. Neurol. Neurosurg. Psychiatry* 70, 506–513.
- Duffau, H., 2005. Lessons from brain mapping in surgery for low-grade glioma: insights into associations between tumour and brain plasticity. *Lancet Neurol.* 4, 476–486.
- Duffau, H., 2006a. Brain plasticity: from pathophysiological mechanisms to therapeutic applications. *J. Clin. Neurosci.* 13, 885–897.

- Duffau, H., 2006b. New concepts in surgery of WHO grade II gliomas: functional brain mapping, connectionism and plasticity – a review. *J. Neurooncol.* 79, 77–115.
- Duffau, H., 2009a. A personal consecutive series of surgically treated 51 cases of insular WHO grade II glioma: advances and limitations. *J. Neurosurg.* 110, 696–708.
- Duffau, H., 2009b. Does post-lesional subcortical plasticity exist in the human brain? *Neurosci. Res.* 65, 131–135.
- Duffau, H., 2009c. Surgery of low-grade gliomas: towards a 'functional neurooncology'. *Curr. Opin. Oncol.* 21, 543–549.
- Duffau, H., Sichez, J.P., Lehericy, S., 2000. Intraoperative unmasking of brain redundant motor sites during resection of a precentral angioma: evidence using direct cortical stimulation. *Ann. Neurol.* 47, 132–135.
- Duffau, H., Capelle, L., Sichez, N., Denvil, D., Lopes, M., Sichez, J.P., Bitar, A., Fohanno, D., 2002. Intraoperative mapping of the subcortical language pathways using direct stimulations. An anatomo-functional study. *Brain* 125, 199–214.
- Duffau, H., Capelle, L., Denvil, D., Sichez, N., Gatignol, P., Lopes, M., Mitchell, M.C., Sichez, J.P., Van Effenterre, R., 2003. Functional recovery after surgical resection of low grade gliomas in eloquent brain: hypothesis of brain compensation. *J. Neurol. Neurosurg. Psychiatry* 74, 901–907.
- Duffau, H., Khalil, I., Gatignol, P., Denvil, D., Capelle, L., 2004. Surgical removal of corpus callosum infiltrated by low-grade glioma: functional outcome and oncological considerations. *J. Neurosurg.* 100, 431–437.
- Duffau, H., Gatignol, P., Mandonnet, E., Peruzzi, P., Tzourio-Mazoyer, N., Capelle, L., 2005. New insights into the anatomo-functional connectivity of the semantic system: a study using cortico-subcortical electrostimulations. *Brain* 128, 797–810.
- Duffau, H., Leroy, M., Gatignol, P., 2008a. Cortico-subcortical organization of language networks in the right hemisphere: an electrostimulation study in left-handers. *Neuropsychologia* 46, 3197–3209.
- Duffau, H., Peggy Gatignol, S.T., Mandonnet, E., Capelle, L., Taillandier, L., 2008b. Intraoperative subcortical stimulation mapping of language pathways in a consecutive series of 115 patients with grade II glioma in the left dominant hemisphere. *J. Neurosurg.* 109, 461–471.
- Duffau, H., Thiebaut de Schotten, M., Mandonnet, E., 2008c. White matter functional connectivity as an additional landmark for dominant temporal lobectomy. *J. Neurol. Neurosurg. Psychiatry* 79, 492–495.
- Duffau, H., Gatignol, P., Moritz-Gasser, S., Mandonnet, E., 2009. Is the left uncinate fasciculus essential for language? A cerebral stimulation study. *J. Neurol.* 256, 382–389.
- Evans, A.C., Marrett, S., Neelin, P., Collins, L., Worsley, K., Dai, W., Milot, S., Meyer, E., Bub, D., 1992. Anatomical mapping of functional activation in stereotactic coordinate space. *Neuroimage* 1, 43–53.
- Gaillard, W.D., Balsamo, L., Xu, B., Grandin, C.B., Braniecki, S.H., Papero, P.H., Weinstein, S., Conry, J., Pearl, P.L., Sachs, B., Sato, S., Jabbari, B., Vezina, L.G., Frattali, C., Theodore, W.H., 2002. Language dominance in partial epilepsy patients identified with an fMRI reading task. *Neurology* 59, 256–265.
- Gooya, A., Biros, G., Davatzikos, C., 2010. Deformable registration of glioma images using EM algorithm and diffusion reaction modeling. *IEEE Trans. Med. Imaging* 30, 375–390.
- Guleria, S., Gupta, R.K., Saksena, S., Chandra, A., Srivastava, R.N., Husain, M., Rathore, R., Narayana, P.A., 2008. Retrograde Wallerian degeneration of cranial corticospinal tracts in cervical spinal cord injury patients using diffusion tensor imaging. *J. Neurosci. Res.* 86, 2271–2280.
- Hickok, G., Poeppel, D., 2007. The cortical organization of speech processing. *Nat. Rev. Neurosci.* 8, 393–402.
- Ishitobi, M., Nakasato, N., Suzuki, K., Nagamatsu, K., Shamoto, H., Yoshimoto, T., 2000. Remote discharges in the posterior language area during basal temporal stimulation. *Neuroreport* 11, 2997–3000.
- Kamada, K., Todo, T., Masutani, Y., Aoki, S., Ino, K., Morita, A., Saito, N., 2007. Visualization of the frontotemporal language fibers by tractography combined with functional magnetic resonance imaging and magnetoencephalography. *J. Neurosurg.* 106, 90–98.
- Keidel, J.L., Welbourne, S.R., Lambon Ralph, M.A., 2010. Solving the paradox of the equipotential and modular brain: a computational model of stroke vs. slow-growing glioma. *Neuropsychologia* 48, 1716–1724.
- Kinkingehun, S., Volle, E., Pelegrini-Issac, M., Golmard, J.L., Lehericy, S., du Boisgueheneuc, F., Zhang-Nunes, S., Sossion, D., Duffau, H., Samson, Y., Levy, R., Dubois, B., 2007. A novel approach to clinical-radiological correlations: Anatomic-Clinical Overlapping Maps (AnaCOM): method and validation. *Neuroimage* 37, 1237–1249.
- Kinoshita, M., Yamada, K., Hashimoto, N., Kato, A., Izumoto, S., Baba, T., Maruno, M., Nishimura, T., Yoshimine, T., 2005. Fiber-tracking does not accurately estimate size of fiber bundle in pathological condition: initial neurosurgical experience using neuronavigation and subcortical white matter stimulation. *Neuroimage* 25, 424–429.
- Klein, A., Andersson, J., Ardekani, B.A., Ashburner, J., Avants, B., Chiang, M.C., Christensen, G.E., Collins, D.L., Gee, J., Hellier, P., Song, J.H., Jenkinson, M., Lepage, C., Rueckert, D., Thompson, P., Vercauteren, T., Woods, R.P., Mann, J.J., Parsey, R.V., 2009. Evaluation of 14 nonlinear deformation algorithms applied to human brain MRI registration. *Neuroimage* 46, 786–802.
- Krainik, A., Duffau, H., Capelle, L., Cornu, P., Boch, A.L., Mangin, J.F., Le Bihan, D., Marsault, C., Chiras, J., Lehericy, S., 2004. Role of the healthy hemisphere in recovery after resection of the supplementary motor area. *Neurology* 62, 1323–1332.
- Lawes, I.N., Barrick, T.R., Murugam, V., Spierings, N., Evans, D.R., Song, M., Clark, C.A., 2008. Atlas-based segmentation of white matter tracts of the human brain using diffusion tensor tractography and comparison with classical dissection. *Neuroimage* 39, 62–79.
- LeRoux, P.D., Berger, M.S., Haglund, M.M., Pilcher, W.H., Ojemann, G.A., 1991. Resection of intrinsic tumors from nondominant face motor cortex using stimulation mapping: report of two cases. *Surg. Neurol.* 36, 44–48.
- Lubrano, V., Draper, L., Roux, F.E., 2010. What makes surgical tumor resection feasible in Broca's area? Insights into intraoperative brain mapping. *Neurosurgery* 66, 868–875 discussion 875.
- Mandonnet, E., Delattre, J.Y., Tanguy, M.L., Swanson, K.R., Carpentier, A.F., Duffau, H., Cornu, P., Van Effenterre, R., Alvord Jr., E.C., Capelle, L., 2003. Continuous growth of mean tumor diameter in a subset of grade II gliomas. *Ann. Neurol.* 53, 524–528.
- Mandonnet, E., Capelle, L., Duffau, H., 2006. Extension of paralinguistic low grade gliomas: toward an anatomical classification based on white matter invasion patterns. *J. Neurooncol.* 78, 179–185.
- Mandonnet, E., Jbabdi, S., Taillandier, L., Galanaud, D., Benali, H., Capelle, L., Duffau, H., 2007a. Preoperative estimation of residual volume for WHO grade II glioma resected with intraoperative functional mapping. *Neuro-oncology* 9, 63–69.
- Mandonnet, E., Nouet, A., Gatignol, P., Capelle, L., Duffau, H., 2007b. Does the left inferior longitudinal fasciculus play a role in language? A brain stimulation study. *Brain* 130, 623–629.
- Mandonnet, E., Pallud, J., Fontaine, D., Taillandier, L., Bauchet, L., Peruzzi, P., Guyotat, J., Bernier, V., Baron, M.H., Duffau, H., Capelle, L., 2010a. Inter- and intrapatient comparison of WHO grade II glioma kinetics before and after surgical resection. *Neurosurg. Rev.* 33, 91–96.
- Mandonnet, E., Winkler, P.A., Duffau, H., 2010b. Direct electrical stimulation as an input gate into brain functional networks: principles, advantages and limitations. *Acta Neurochir. (Wien)* 152, 185–193.
- Ojemann, G., Ojemann, J., Lettich, E., Berger, M., 1989. Cortical language localization in left, dominant hemisphere. An electrical stimulation mapping investigation in 117 patients. *J. Neurosurg.* 71, 316–326.
- Pallud, J., Devaux, B., Dumas-Duport, C., Oppenheim, C., Roux, F.X., 2005. Glioma dissemination along the corticospinal tract. *J. Neurooncol.* 73, 239–240.
- Papagno, C., Miracapillo, C., Casarotti, A., Romero Lauro, L.J., Castellano, A., Falini, A., Casaceli, G., Fava, E., Bello, L., 2011. What is the role of the uncinate fasciculus? Surgical removal and proper name retrieval. *Brain* 134, 405–414.
- Peraud, A., Ilmberger, J., Reulen, H.J., 2004. Surgical resection of gliomas WHO grade II and III located in the opercular region. *Acta Neurochir. (Wien)* 146, 9–17 discussion 17–18.
- Rorden, C., Fridriksson, J., Karnath, H.O., 2009. An evaluation of traditional and novel tools for lesion behavior mapping. *Neuroimage* 44, 1355–1362.
- Rosset, A., Spadola, L., Ratib, O., 2004. OsiriX: an open-source software for navigating in multidimensional DICOM images. *J. Digit. Imaging* 17, 205–216.
- Rossini, P.M., Calautti, C., Pauri, F., Baron, J.C., 2003. Post-stroke plastic reorganization in the adult brain. *Lancet Neurol.* 2, 493–502.
- Roux, F.E., Boulanouar, K., Lotterie, J.A., Mejdoubi, M., LeSage, J.P., Berry, I., 2003. Language functional magnetic resonance imaging in preoperative assessment of language areas: correlation with direct cortical stimulation. *Neurosurgery* 52, 1335–1345 discussion 1345–1337.
- Sahin, N.T., Pinker, S., Cash, S.S., Schomer, D., Halgren, E., 2009. Sequential processing of lexical, grammatical, and phonological information within Broca's area. *Science* 326, 445–449.
- Sanai, N., Berger, M.S., 2008. Glioma extent of resection and its impact on patient outcome. *Neurosurgery* 62, 753–764 discussion 264–756.
- Sanai, N., Berger, M.S., 2010. Intraoperative stimulation techniques for functional pathway preservation and glioma resection. *Neurosurg. Focus* 28, E1.
- Sanai, N., Mirzadeh, Z., Berger, M.S., 2008. Functional outcome after language mapping for glioma resection. *N. Engl. J. Med.* 358, 18–27.
- Sanes, J.N., Donoghue, J.P., Thangaraj, V., Edelman, R.R., Warach, S., 1995. Shared neural substrates controlling hand movements in human motor cortex. *Science* 268, 1775–1777.
- Schieber, M.H., Hibbard, L.S., 1993. How somatotopic is the motor cortex hand area? *Science* 261, 489–492.
- Smith, S.M., Jenkinson, M., Woolrich, M.W., Beckmann, C.F., Behrens, T.E., Johansen-Berg, H., Bannister, P.R., De Luca, M., Drobnjak, I., Flitney, D.E., Niazy, R.K., Saunders, J., Vickers, J., Zhang, Y., De Stefano, N., Brady, J.M., Matthews, P.M., 2004. Advances in functional and structural MR image analysis and implementation as FSL. *Neuroimage* 23 (Suppl 1), S208–S219.
- Stam, C.J., 2010. Characterization of anatomical and functional connectivity in the brain: a complex networks perspective. *Int. J. Psychophysiol.* 77, 186–194.
- Taphoorn, M.J., Klein, M., 2004. Cognitive deficits in adult patients with brain tumours. *Lancet Neurol.* 3, 159–168.
- Thiebaut de Schotten, M., Urbanski, M., Duffau, H., Volle, E., Levy, R., Dubois, B., Bartolomeo, P., 2005. Direct evidence for a parietal-frontal pathway subserving spatial awareness in humans. *Science* 309, 2226–2228.
- Thiebaut de Schotten, M., Ffytche, D.H., Bizzi, A., Dell'Acqua, F., Allin, M., Walshe, M., Murray, R., Williams, S.C., Murphy, D.G., Catani, M., 2011. Atlasing location, asymmetry and inter-subject variability of white matter tracts in the human brain with MR diffusion tractography. *Neuroimage* 54, 49–59.
- Tzourio-Mazoyer, N., Josse, G., Crivello, F., Mazoyer, B., 2004. Interindividual variability in the hemispheric organization for speech. *Neuroimage* 21, 422–435.
- Walker, D.G., Kaye, A.H., 2003. Low grade glial neoplasms. *J. Clin. Neurosci.* 10, 1–13.
- Wessels, P.H., Weber, W.E., Raven, G., Ramaekers, F.C., Hopman, A.H., Twijnstra, A., 2003. Supratentorial grade II astrocytoma: biological features and clinical course. *Lancet Neurol.* 2, 395–403.
- Witwer, B.P., Moftakhar, R., Hasan, K.M., Deshmukh, P., Haughton, V., Field, A., Arfanakis, K., Noyes, J., Moritz, C.H., Meyerand, M.E., Rowley, H.A., Alexander, A.L., Badie, B., 2002. Diffusion-tensor imaging of white matter tracts in patients with cerebral neoplasm. *J. Neurosurg.* 97, 568–575.
- Woolrich, M.W., Jbabdi, S., Patenaude, B., Chappell, M., Makni, S., Behrens, T., Beckmann, C., Jenkinson, M., Smith, S.M., 2009. Bayesian analysis of neuroimaging data in FSL. *Neuroimage* 45, S173–S186.